

Pig Mandible as a Valuable Tool to Improve Periodontal Surgery Techniques

Mariana S. Raghianti Zangrando¹, Adriana C. P. Sant'Ana¹, Sebastião L. A. Gregghi¹,
Maria Lucia R. de Rezende¹ & Carla A. Damante¹

¹ Department of Prosthodontics, Discipline of Periodontology, Bauru Dental School, University of São Paulo, São Paulo, Brazil

Correspondence: Mariana S. Raghianti Zangrando, Bauru Dental School, University of São Paulo, Alameda Octavio Pinheiro Brisolla 9-75, São Paulo, Brazil. Tel: 55-14-3235-8577. E-mail: mariana@fob.usp.br

Received: July 23, 2014 Accepted: August 24, 2014 Online Published: September 26, 2014

doi:10.5539/ies.v7n10p82

URL: <http://dx.doi.org/10.5539/ies.v7n10p82>

Abstract

Clinical education in dental practice is a challenge for professionals and students. The traditional method of clinical training in Periodontology usually is based on following the procedure and practicing under supervision, until achieving proficiency. However, laboratory practice is required before direct care in patients. Specific anatomic plastic models can be useful, but animal cadaver models provide better similarity to human tissues. The objectives of this study are to describe a model for training periodontal surgical techniques in a pig mandible model and evaluate the effect of the program on student's progress. Several surgical procedures were critically analyzed and trained with graduate students, including: gingivoplasty/gingivectomy, distal wedge procedure, frenectomy, internal bevel incision, total/partial flap, furcation access, gingival grafts and suture techniques. These procedures were theoretically reminded before laboratory practice. A questionnaire was applied concerning aspects of the laboratory and students provided their concepts and impression. The majority of the students scored positive aspects related to laboratory practice. Based on the questionnaire answers, we observed that the practical laboratory helped in the assimilation of the theoretical content and improved skills in the practice of periodontal surgical techniques. Graduate students were also more confident in performing these surgical procedures directly on the patient. Another positive aspect is the similarity of pig teeth and gingival tissues to human correspondent, being especially appropriate for surgical demonstration and training with excellent reproducibility. The laboratorial practice with pig mandible for graduate students was a valuable tool to improve periodontal surgical techniques.

Keywords: graduate training, periodontal surgery, pig model

1. Introduction

Teaching periodontal surgical procedures for graduate students can be a challenge since the process of learning comprehends the understanding of theoretical content and the development of manual skills. The traditional method of clinical training in Periodontology usually is based on follow the procedure by repetition and after that, practice under the supervision of the teacher, until achieving proficiency. However, a laboratory practice is required before direct care in patients. Some plastic mannequins that reproduce periodontal tissues were extensively used in past decades (Ruhling et al., 2002; König et al., 2002). Nevertheless, the texture and handling of this material is different from the human correspondents. A correct flap management and sutures techniques execution can be difficult and dissimilar from the human periodontal tissues.

Pigs are one of the first species to be domesticated and represent an important livestock species with nearly 500 different breeds with a worldwide distribution (Rothschild, 2004). Pigs and mini pigs became a very common and preferred biomedical model (Sasaki et al, 2010). These animals are considered as an experimental model in many biomedical fields due to their apparent resemblance to the human anatomy (Stembírek, Kyllar, Putnová, Stehlík, & Buchtová, 2012). Other important aspects of this animal model are economic advantages and ethical reasons (Stembírek et al., 2012). One study compared the anatomic features of pigs to humans and found numerous similarities, establishing this animal as a model in some areas of biomedical and pharmacological research (Stembírek et al., 2012).

In recent years, different periodontal procedures were established, as well as ressective and regenerative

procedures and periodontal plastic surgery. Instead of simply demonstrating this variety of surgical techniques, a teaching model for graduate students must include laboratorial surgical practice before performing periodontal surgical procedures in human patients. Pig mandibles have been used for oral surgical training since the mid-1960s (Stacey, 1967; Bonnette, 1969). This animal model can be useful also for training of periodontal surgical techniques. The anatomical similarity between pig mandible and human tissues provides an excellent periodontal surgical training for graduate students. The objectives of this paper are to demonstrate numerous periodontal surgical techniques using a pig mandible and to evaluate the effect of the program on student's progress. The training of surgical techniques included: gingivoplasty/gingivectomy, distal wedge, frenectomy, internal bevel incision, partial/total flap management, free gingival graft, subepithelial connective tissue graft technique, furcation access for resective or regenerative procedures and suture techniques. Questions regarding laboratorial practice in pig mandible and the suitability of this model for different surgical procedures were addressed for graduate students from Periodontology Specialization Course at Bauru Dental School, University of São Paulo.

2. Materials and Methods

This study was registered in *Plata forma Brasil* (CONEP–National Health Council–National Committee for Ethics in Research) number 292047, in 08 May/2014, in agreement with the guidelines of the Helsinki Declaration as revised in 1975. The laboratory practice was conducted using 25 pig mandibles, one for each student. Mandibles were removed from the animals and cleaned in the abattoir according to our instructions. Only healthy samples with unimpaired teeth, gingival tissues and alveolar mucosa were selected. Mandibles were maintained at refrigerator with no fixatives. Prior to laboratory practice, frozen mandibles were maintained at room temperature until tissues were soft and pliable.

Prior to laboratory sessions with the model system, the students received lectures and had the opportunity to review periodontal surgical procedures. Following a short review and discussion of the theory related to the procedure to be attempted, the students were instructed to organize the operative desk with periodontal instruments and pig mandible (Figure 1a). All surgical instrumentals and materials used were sterilized. The laboratory practice was performed in two days with total duration of 16 hours.

The periodontal procedures performed in pig mandible laboratory were:

- 1) Distal wedge procedure (distal to most posterior molar teeth): use of number 15 C surgical scalpel blade to perform a triangular wedge. Incisions are placed creating the apex of the triangle close to the hamular notch and the base of the triangle next to the distal surface of the terminal tooth (Figure 1b);
- 2) Gingivoplasty/gingivectomy (buccal and lingual aspect of anterior teeth): the graduate student was able to use a periodontal probe to measure periodontal pocket depth. After measurements, external bevel incisions were planned and excisions of the enlarged tissue were made using the Kirkland knife, Orban's knife and Goldman Fox nippers (Figure 1c);
- 3) Frenectomy (anterior region): surgical removal of the frenum with number 15C surgical scalpel blade (Figure 1d);

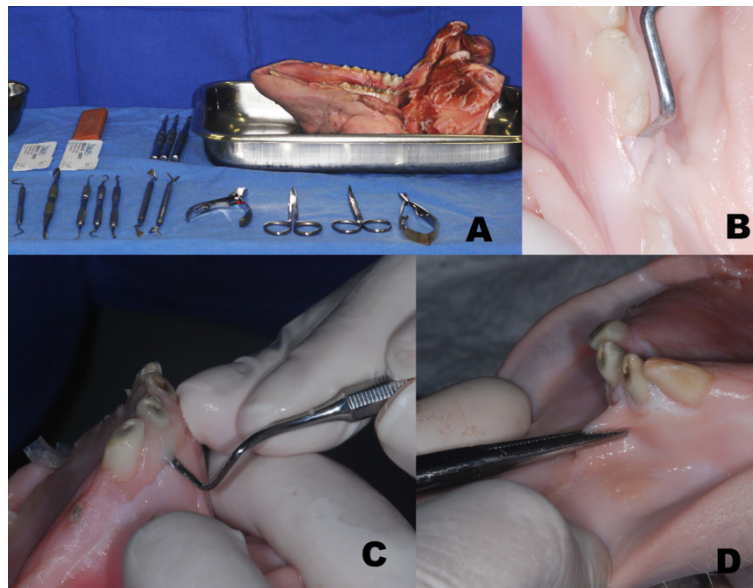


Figure 1. a. Operative desk with periodontal instruments and pig mandible; b. Distal wedge procedure at distal aspect of molar teeth; c. Utilization of Orban's knife for gingivoplasty/gingivectomy techniques in buccal aspect of anterior teeth; d. Frenectomy at anterior region

- 4) Internal bevel incision: starts at a distance of about 1mm from the gingival margin aiming at the bone crest (Figure 2a);
- 5) Total/partial flap management: student could perform full thickness flap with periosteum reflected to expose the underlying bone, using a periosteal elevator (Figure 2b); partial thickness flap prepared with number 15C scalpel blade and periosteum remains covering the bone (Figure 2c);
- 6) Furcation access for resective or regenerative procedures: student could practice osteotomy (Figure 2d) and odontoplasty.

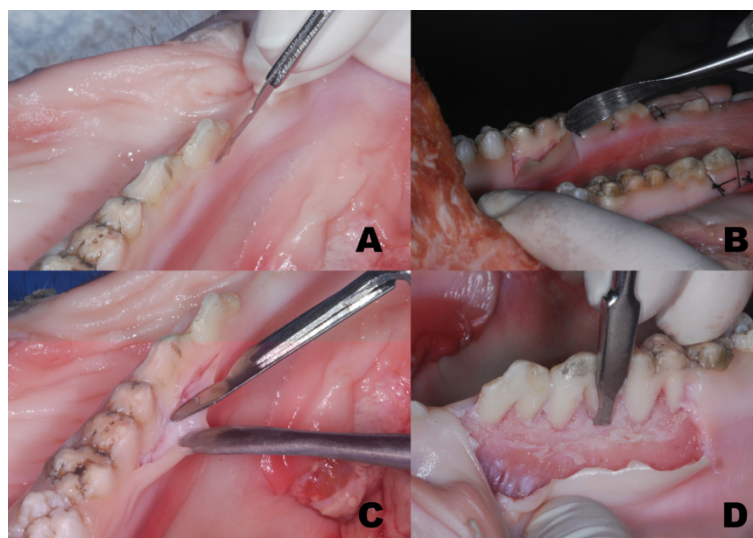


Figure 2. a. Internal bevel incision at lingual aspect of molar teeth; b. Full thickness flap using a periosteal elevator; c. Partial thickness flap prepared with number 15 C scalpel blade; d. Furcation access for resective procedures

7) Regenerative procedures: use of membranes (paper or tin foil) and bone grafts (oat flakes) (Figure 3a);

8) Free gingival graft/ Subepithelial connective tissue graft technique: gingival graft was removed from donor site in the internal side of the mandible (Figure 3b). Receptor site with partial thickness flap was prepared. (Figure 3c);

8) Suture techniques: training on interrupted sutures, mattress sutures, sling sutures and periosteal sutures (Figure 3d).

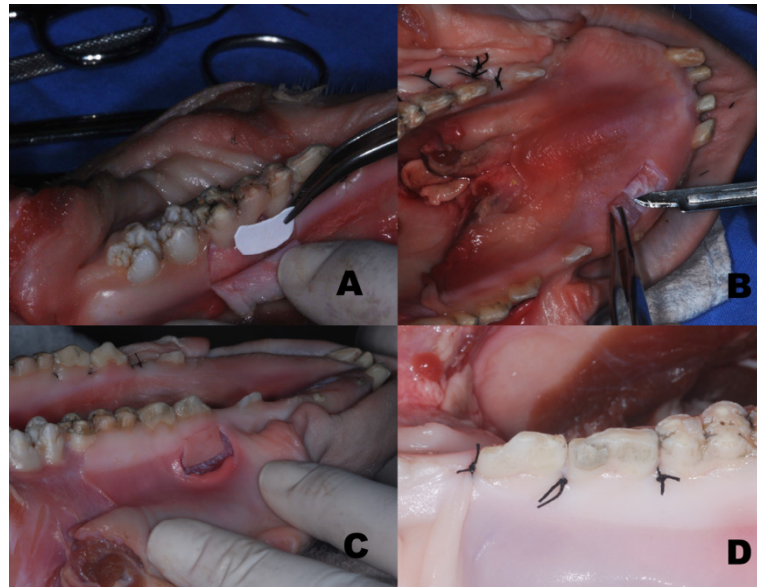


Figure 3. a. Furcation access for regenerative procedures; b. Free gingival graft-donor site; c. Gingival graft at receptor site; d. Interrupted sutures

After teaching session, mandibles were collected and taken to a special category waste of our Institution. The probable risk for infection from manipulating this animal cadaver model is considered minimal (Stacey, 1985).

After 6 months of the laboratory practice, a questionnaire was applied about aspects of pig mandible laboratory and periodontal surgical techniques executed. The questionnaire was distributed to students from Periodontology Specialization Course at Bauru Dental School, University of São Paulo. A total of 7 questions were formulated addressing the aspects of laboratory and the usefulness of the knowledge received. The questionnaire was composed by five concepts regarding the learning experience: harmful, unnecessary, indifferent, good, fundamental. An essay question was made about positive and negative aspects of the periodontal laboratory with animal model.

3. Results

A total of 25 graduate students filled out questionnaires on periodontal surgical laboratory in pig mandible model. The questionnaire included the following questions:

- 1) Contribution of the lab for the periodontal surgical techniques knowledge;
- 2) Did lab help in understanding the theoretical part;
- 3) Did lab help in the recognition of surgical instruments;
- 4) Did lab help in the use of each surgical instrument;
- 5) Did lab help reproduce the surgical technique appropriately in your patients;
- 6) Did lab give you reliability for patient' streatment;
- 7) Did lab is useful for learning different sutures;

In these 7 questions, it was asked for students to provide one of these concepts: harmful, unnecessary, indifferent, good or fundamental.

Considering the first question, 88% of the students answered that the contribution of the lab for the periodontal surgical techniques knowledge was fundamental and 12% answered that was good. Eight four percent of the graduates considered the lab fundamental for understanding the theoretical part (question 2) and 16% considered good. In question number 3 about recognition of surgical instruments, 80% reported that the lab was fundamental and 20% that was good. For 52%, the lab practice was fundamental for use of each surgical instrument (question 4) and for 48% was good. Students were asked about the usefulness of the lab regarding the reproducibility of surgical technique appropriately in patients (question 5). Sixty four percent considered fundamental and 36% good. Question number 6 about the reliability for patient's treatment, 72% felt that lab was fundamental, 24% good and 4% indifferent. The last question about suture management, 80% stated that the lab was fundamental and 20% considered good. The overall percentages of responses given by the students in the questionnaire are shown in Figure 4.

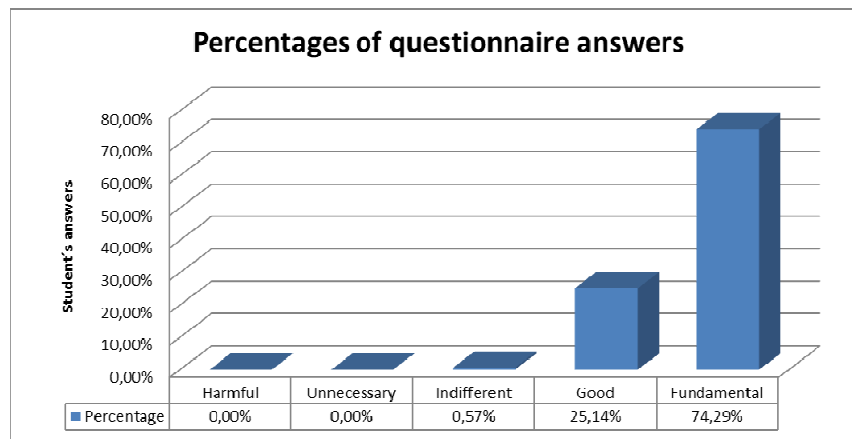


Figure 4. Mean percentages of graduate student's responses

The essay question was about positive and negative aspects considering laboratory with pig mandible. Forty eight percent of the students emphasized that the practice lab had only positive points, 44% considered negative and positive aspects and 8% did not answer.

Positive aspects of the periodontal laboratory with animal model were reported concerning improved knowledge of the instruments, enhanced ability to execute different periodontal techniques, reliability to treat surgical patients and similarity concerning human and pig tissues. Negative aspects were related to gingival tissue in pig mandible, some students had difficult to manipulate flaps because of the more rigid consistence of pig tissue. Another negative aspect pointed out was the unfavorable odor of the mandible.

4. Discussion

Periodontal education for graduate students involves not only development of both diagnostic and treatment planning but also manual skills. The goals are to achieve a high level of education that provides all means for evidence based periodontal care (Sanz & Meyle, 2010). In a survey designed to explore in some detail the teaching methods utilized during the preclinical training, the most commonly used methods are slides (67%), live demonstration (61%), DVD/CDs (48%), and animal cadavers (45%). The least commonly used methods are online courses (6%), computer-assisted learning (including computer simulation, 12%), and various surgical mannequins (15%) (Ghiabi & Taylor, 2010). For example, the tenacity of the artificial gum material demands the use of unusual cutting techniques which do not help the student to learn how to handle soft tissue (Gumming & Glavind, 1972). We had already made a practice lab with ox mandible, but the gingival tissue is more difficult to handle and provides greater anatomical differences compared to human tissues and teeth. The results of our evaluation indicated that pig mandible is a valuable instrument for teaching and enhancing periodontal surgical abilities. Our learning process that involved exposure of the theoretical content and review of the concepts prior laboratory practice obtained excellent results with graduate students regarding patient care.

Another important aspect of this animal model is that pig teeth and gingival tissues have similar size and shape as their human equivalents. Some surgical periodontal procedures as frenectomy, gingivectomy/gingivoplasty was demonstrated and trained in anterior area of mandible with excellent reproducibility. The similarity between

premolars and molars in pigs and humans permitted demonstration of different forms of incisions, flaps and sutures. The posterior region was used for training of internal bevel incision, total and partial flap management, furcation access and gingival grafts receptors sites. Students also accomplished bone procedures (osteotomy/osteoplasty) related to resective surgery. Gumming and Glavind (1972) affirmed that bone in the pig mandible was found to be denser compared to human, but little difficulty was encountered in cutting it. The same aspect was observed by our students. Regenerative techniques were trained simulating the use of membranes with a paper or tin foil and bone grafts with oat flakes. Gingival grafts were obtained from the internal side of the mandible in an edentulous area similar to human palate. Flaps could be secure with interrupted, mattress, sling and periosteal sutures, with excellent reproducibility. The pig mandible provided a remarkable representation of the human in terms of size, morphology and tissue texture. Other differences between laboratory practice and clinical care of patients are related to absence of bleeding or salivation, difficulties related to mouth opening and movement of tongue, lips and cheek. However, teachers emphasized the presence of these factors during patient care. Social factors, individual beliefs and religion may limit the use of this animal model.

After completing the lab, students initiated clinical practice with patients. During surgical procedures, students were individually monitored and guided with the support of the professors. The knowledge of students who underwent laboratory practice was compared to students who did not attend the laboratory. Both received theoretical content and individual instructions about periodontal procedures, but professionals observed that students who did not participate of the lab, presented inferior clinical performance compared to attendant students. The students felt that practicing on the pig mandible had improved their understanding of the theoretical part, using and recognition of surgical instruments. Additionally, laboratory helped them to reproduce surgical techniques appropriately in patients, providing reliability in patient's treatment. Although some students have pointed out some negative aspects, the questionnaire answers showed that they truly appreciated the sessions and felt they were beneficial as later verified by their clinical performance.

5. Conclusion

The questionnaire results and favorable clinical performance observed in graduate students indicated that the laboratory practice with pig mandible were beneficial. Therefore, pig mandible is a valuable tool to learn periodontal surgery techniques.

References

- Bonnette, G. H., & Hayward, J. R. (1969). Introductory approach to the study of oral surgery: Preclinical laboratory. *Journal of Dental Education*, *33*, 350-354.
- Ghiabi, E., & Taylor, K. L. (2010). Teaching methods and surgical training in North American graduate Periodontics programs: Exploring the landscape. *Journal of Dental Education*, *74*, 618-627.
- Gumming, B. R., & Glavind, L. (1972). Utilization of animal material in the teaching of periodontal surgery. *Scandinavian Journal of Dental Research*, *80*, 524-528.
- König, J., Rühling, A., Schlemme, H., Kocher, T., Schwahn, C., & Plagmann, H. C. (2002). Learning root debridement with curettes and power-driven instruments in vitro: The role of operator motivation and self-assessment. *European Journal of Dental Education*, *6*, 169-175. <http://dx.doi.org/10.1034/j.1600-0579.2002.00258.x>
- Rothschild, M. F. (2004). Porcine genomics delivers new tools and results: This little piggy did more than just go to market. *Genetics Research*, *83*, 1-6. <http://dx.doi.org/10.1017/S0016672303006621>
- Ruhling, A., Schlemme, H., König, J., Kocher, T., Schwahn, C., & Plagmann, H. C. (2002). Learning root debridement with curettes and power-driven instruments. Part I. A training program to increase effectivity. *Journal of Clinical Periodontology*, *29*, 622-629. <http://dx.doi.org/10.1034/j.1600-051X.2002.290706.x>
- Sanz, M., & Meyle, J. (2010). Scope, competences, learning outcomes and methods of periodontal education within the undergraduate dental curriculum: A Consensus report of the 1st European workshop on periodontal education—position paper 2 and consensus view 2. *European Journal of Dental Education*, *14*(Suppl. 1), 25-33. <http://dx.doi.org/10.1111/j.1600-0579.2010.00621>
- Sasaki, R., Watanabe, Y., Yamato, M., Aoki, S., Okano, T., & Ando, T. (2010). Surgical anatomy of the swine face. *Laboratory Animals*, *44*, 359-363. <http://dx.doi.org/10.1258/la.2010.009127>
- Stacey, G. C. (1967). The pig's head as a teaching device in oral surgery. *Australian Dental Journal*, *12*, 160-164. <http://dx.doi.org/10.1111/j.1834-7819.1967.tb02192.x>
- Stacey, G. C. (1985). A laboratory for teaching oral-surgical techniques. *Journal of Dentistry*, *13*, 318-322.

[http://dx.doi.org/10.1016/0300-5712\(85\)90028-4](http://dx.doi.org/10.1016/0300-5712(85)90028-4)

Stembírek, J., Kyllar, M., Putnová, I., Stehlík, L., & Buchtová, M. (2012). The pig as an experimental model for clinical craniofacial research. *Laboratory Animals*, 46, 269-279. <http://dx.doi.org/10.1258/la.2012.012062>

Copyrights

Copyright for this article is retained by the author(s), with first publication rights granted to the journal.

This is an open-access article distributed under the terms and conditions of the Creative Commons Attribution license (<http://creativecommons.org/licenses/by/3.0/>).